

The role of hepatic biopsy in liver graft evaluation during liver procurement

M.S. Novruzbekov, O.D. Olisov, V.A. Gulyaev, K.N. Lutsyk,
E.I. Ryaboshtanova, A.S. Tertychnyy, O.F. Vostrikova, A.S. Rozhenkov
*N.V. Sklifosovsky Research Institute for Emergency Medicine, Moscow,
Russia*

Correspondence to: Murad S. Novruzbekov, Cand.Med.Sci., Head of the Scientific Department for Liver Transplantation, N.V. Sklifosovsky Research Institute for Emergency Medicine, Moscow, Russia, e-mail: N.M.S@bk.ru

Received: 12 October 2016

Abstract. *Using a steatotic graft in liver transplantation (LT) can lead to a poor function and high mortality. The role of the rapid liver graft biopsy processing was studied. The liver grafts of potential donors were assessed for hepatic steatosis.*

Material and methods. *The study included 341 cases of cadaveric donor liver transplantations. Patients were divided in two groups: the study group where the rapid graft biopsy processing was performed (n=163) and the comparison group (n=178) without biopsy processing. Livers with macrosteatosis of over 50% of graft parenchyma or with severe necrosis and structural damage were discarded.*

Results. *The rates of ischemic reperfusion injury (IRI), initial poor graft function (IPGF), and primary graft non-function (PGNF) were significantly lower in the study group. There were no significant differences between two groups in cold ischemia time.*

Conclusion: *rapid histological examination provides a useful tool to avoid life threatening LT complications such as severe IRI, IPGF, and PNF.*

Keywords: liver transplantation, reperfusion injury, steatosis, graft function.

Liver transplantation has been the only definite treatment technique for patients with end-stage diffused and some focal liver diseases. Despite an obvious increase in the number of surgical procedures performed annually, the demands of the Waiting list are met by no more than one-third only. An acute shortage of donor organs has initiated the search for new solutions to the problem of organ donation. Currently, the donor pool can be significantly increased thanks to liver fragment transplantation, such as a related donor transplant or split-transplantation. However, there is another more likely and more feasible way in transplantation practice: that is using organs from so-called expanded criteria donors (ECDs). However, organ transplantation from ECDs is known as associated with an increased risk of complications, up to a graft non-function [1-4]. One of the most important factors affecting the primary liver graft function is the degree of the graft fatty degeneration [5, 6]. The proposed principles of organ visual assessment should be referred to subjective methods that, in turn, can lead both to overdiagnosis, or to critical under-evaluation of the organ [7]. In other words, in some cases, the visual assessment method can either contribute to an unjustified donor withdrawal from liver donation, or subject the recipient's life to a tremendous risk in the event of an erroneous assessment of the graft quality.

The aim of the study was to investigate the role of the rapid histologic examination technique in assessing the quality of the liver planned for transplantation.

Material and methods. The study was based on a retrospective analysis of the results of orthotopic cadaveric liver transplantation performed in 341 patients in the period from November 2000 to December 2015. The patients were divided into two groups with respect to the method of assessing the quality of a potential donor organ.

The first group included the recipients (n=178; 52.2%) operated on in the period from 2000 to October 2011 in whom the donor liver had been evaluated on the basis of the cumulated data resulted from objective methods (clinical, laboratory, instrumental tests), and the data of visual assessment of the potential donor organ.

The second group included the patients (n = 163 or 47.8%) operated on in the period from October 2011 to December 2015 in whom the standard methods of donor liver assessment had been complemented with the rapid histologic study of the graft.

A biopsy was performed before the start of cold perfusion; the biopsy sample was obtained by excising a tissue fragment from segment III of the liver. The obtained sample of liver tissue was immediately immersed in a 10% formalin solution, and then sent for rapid histologic examination. Staining with hematoxylin and eosin was performed using Harris Hematoxylin (BioOptica, Italy) for rapid histology that reduced the time of processing. The presence of lipids was demonstrated by using a standard staining technique with Oil Red (Bio-Optica, Italy). The graft cold perfusion was performed only after obtaining histological findings.

The main parameters studied at histological examination were the integrity of liver histoarchitectonics, the presence or absence of gross structural alterations, the presence or absence of macrovesicular and

microvesicular steatosis, and its prevalence in the biopsy sample area expressed in percentage.

The criteria for discarding the donor organ included an extremely deranged liver architectonics and/or macrovesicular fatty degeneration of more than 50% of the graft parenchyma identified by rapid graft biopsy processing. In the absence of gross morphological alterations, degree of fatty degeneration was considered an acceptable in macrovesicular steatosis involving under 50% of graft parenchyma.

Postoperatively, the graft quality was assessed by the functional viability of the liver and the IRI severity. The IRI severity was graded considering the enzymemia level with its peaks recorded during the first postoperative week. The increased alanine aminotransferase (ALT) activity was considered as a mild IRI at ALT level up to 1000 U/L, and as a moderate IRI at ALT from 1000 to 2500 U/L. The ALT values over 2500 U/L were classified as a severe IRI.

Statistical analysis was performed using Statistica 10.0 Software package using the descriptive statistics methods, χ^2 -test, and Student's t-test. Differences were considered statistically significant at $p < 0.05$.

Results

The donors' age ranged from 18 to 69 years, the mean age being 39.7 ± 11.5 years. In 77 (22.8%) of 341 (100%) cases, the donors were over 50 years old. The cold ischemia time for the graft varied from 180 to 810 minutes, the mean value being 444 ± 108 minutes. The mean extent of macrovesicular fatty degeneration was $16 \pm 14\%$, ranging from 0 to 50% (Fig. 1).

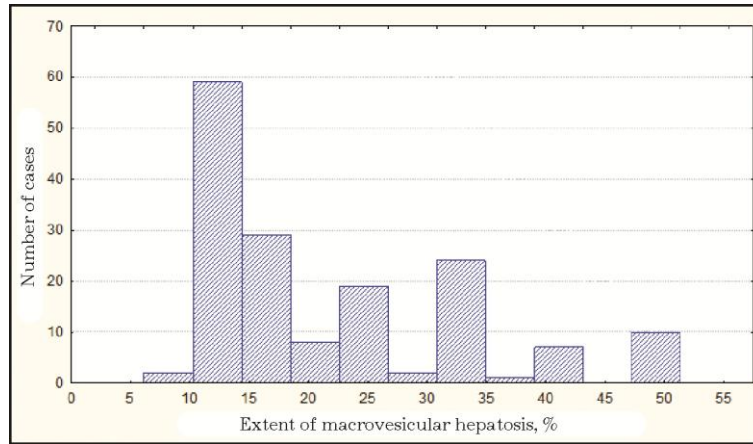


Fig. 1. The distribution of histological examination results with respect to fatty degeneration degree as assessed by the donor liver biopsy

The retrospective analysis of postoperative ALT changes over time demonstrated a lower incidence of moderate and severe degree IRI recorded in the patients with pre-transplant histological assessment of the graft compared to that in the first group of patients. The incidence of moderate and severe IRI was 24.7% and 12.9%, respectively, in the first group of patients, and equal to 14.7% and 5.6%, respectively, in the patients with pre-transplant histological evaluation of the graft. The differences were statistically significant (Table. 1).

Table 1. The patient distribution in the postoperative period with respect to the severity of ischemic reperfusion injury (IRI) (p = 0.001)

IRI severity	Without rapid biopsy processing (N = 178)	Preoperative rapid biopsy processing (N = 163)
Mild	111 (62.4%)	130 (79.7%)

(ALT lower 1000 U/L)		
Moderate (ALT 1000-2500 U/L)	44 (24.7%)	24 (14.7%)
Severe (ALT over 2500 U/L)	23 (12.9%)	9 (5.6)

Those data were confirmed by t-test where the enzymemia mean values were 1312.6 and 775.6 U/L for the first and second groups of patients, respectively. (Fig. 2).

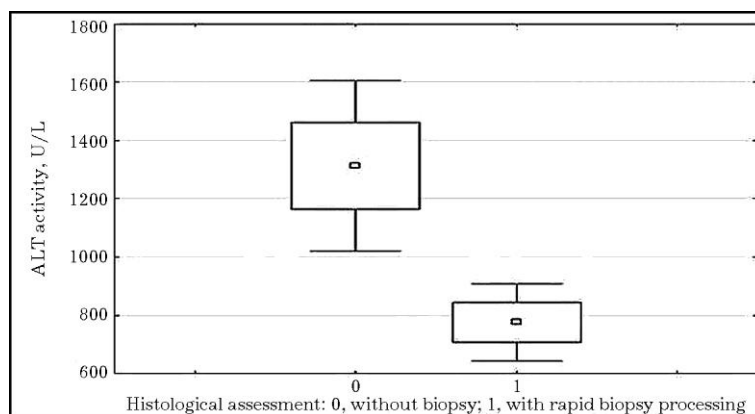


Fig. 2. Rapid biopsy processing and the enzymemia level after orthotopic liver transplantation (p = 0.001)

The irreversible liver failure developing in the early post-transplant period was identified in 15 recipients (4.4%). The critical impairment of the liver graft function correlated with the IRI severity. So, among 15 cases (100%) of poor graft function (primary graft non-function, initial poor graft function), a severe IRI took place in 11 cases (73.3%) (Table. 2).

Table 2. The IRI effect on the liver graft function (p = 0.00005)

IRI severity	Satisfactory liver function	Severe liver graft dysfunction	Total
Mild (ALT lower 1000 U/L)	239 (99.1%)	2 (0.9%)	241 (100%)
Moderate (ALT 1000-2500 U/L)	66 (97%)	2 (3%)	68 (100%)
Severe (ALT over 2500 U/L)	21 (65.7%)	11 (34.3%)	32 (100%)

A retrospective analysis demonstrated that the critical impairment of the liver function occurred significantly less frequently in the group of patients with preoperative histological assessment of the graft than in the first group making 0.6%, and 7.8%, respectively (Table. 3).

We should note that in the group of patients with pre-transplant histological examination of donor liver, no cases of critical liver failure occurred with the graft obtained from donors of an older age group (over 50 years old).

Table 3. The role of preoperative histological evaluation in the predictive assessment of liver graft function (p = 0.001)

Primary graft function	OLT without rapid	Preoperative rapid
-------------------------------	--------------------------	---------------------------

	biopsy processing (N = 178)	liver graft biopsy processing (N = 163)
Satisfactory	164 (92.2%)	162 (99.4%)
The primary graft non- function or initial poor graft function	14 (7.8%)	1 (0.6%)
Total	178 (100%)	163 (100%)

The cold ischemia times in the patients from the group of the rapid liver graft biopsy processing and the comparison group were 403 ± 103 , and 444 ± 112 minutes, respectively; there were no statistically significant differences between the groups (Fig. 3).

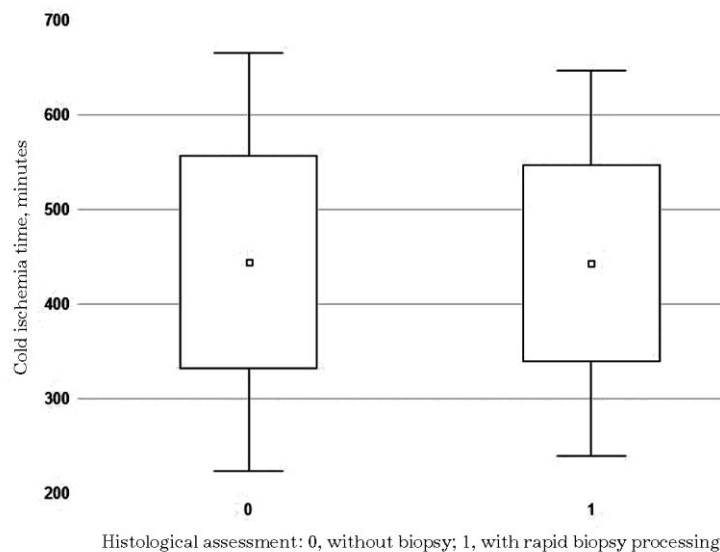


Fig. 3. Graft cold ischemia time (p = 0.9)

Discussion

Functional viability of the donor organ is essential for a successful liver transplantation; that is why an objective assessment of the graft quality is paramount in making correct decisions on the organ use. A severe liver graft dysfunction is generally reported in at least 10% of cases, the incidence of primary graft non-function (PGNF) makes no less than 5%. Despite many of the proposed criteria, the terms "early graft dysfunction" or "poor graft function" have not been clearly defined and universally accepted so far; and the degree of impaired graft function can vary in the early postoperative period from a mild organ dysfunction with a slow recovery to a completely absent function defined as PGNF [1]. According to United Network for Organ Sharing (UNOS) recommendations, the PGNF is defined as an irreversible loss of liver function requiring an urgent retransplantation within the first 10 days after OLT. PGNF should be regarded as being characterized by significant increases in the aspartate aminotransferase (AST) activity (> 5000 U/L), in INR (international normalized ratio) (> 3.0), and by the presence of acidosis ($\text{pH} \leq 7.3$ or increased lactate levels twice as high of normal values) [8].

The IRI severity is a reliable marker of the liver graft function. The most informative in determining the IRI severity are the laboratory tests for cytolysis markers (ALT and AST peak values in the first 24-72 hours), the dynamics of bilirubinemia values, and coagulation status (INR) by the end of the 7-th postoperative day. We should note that cytolysis grading, and the timing of its evaluation in assessing the IRI severity may vary considerably in different proposed classification systems [9-14].

Most authors admit that it is impossible to identify one dominant risk factor in the genesis of a severe primary graft dysfunction. The multifactorial

nature of PGNF has been confirmed by the influence of such donor-associated factors as the age, hemodynamic parameters, constitutional structure peculiarities, homeostasis impairments, cold ischemia time, etc. [4, 8, 9, 15]. No doubt, the morphofunctional state of the donor liver is an essential component that determines the success or failure of a coming transplantation. The negative impact of disseminated macrovesicular fatty degeneration on the liver graft function has been confirmed by numerous studies: disseminated macrosteatosis is an independent risk factor of severe and sometimes irreversible dysfunction: the more pronounced is the macrovesicular fatty degeneration of the liver, the higher will be the IRI severity [2, 9, 15-18]. It is also important to note that in cold ischemia times exceeding the standard values, the graft affected with disseminated macrosteatosis would be exceptionally vulnerable to a severe ischemic injury [1, 2, 4, 8, 19]. An expert estimate based on visual inspection only is not always able to detect a mild to moderate form of fatty degeneration. In this connection, the data obtained at visual inspection of the liver can not be regarded as an objective method of organ assessment, and the histological study is the only way that is able to give the answer to the question on the fatty degeneration degree in the potential graft. Currently, a histological examination of the liver is the gold standard in determining the organ morphological and functional suitability for transplantation [7, 20, 21]. However, despite all the advantages of the rapid histological evaluation, this preoperative assessment method has not been routinely used [21-23].

What degree of the graft fatty degeneration is acceptable in planning the OLT remains a matter of debate. So, Dutkowski et al. (2012) in their study showed a relatively safe macrovesicular fatty degeneration not exceeding 30% of the graft parenchyma. According to M. Angelico (2005),

the prevalence of macrovesicular steatosis over 25% is the factor of marginality adversely affecting the graft and recipient survival. R. Ploeg et al. (1993) and A. Nanashima et al. (2002) in their series used a three-level grading of macrovesicular fatty degeneration, which defined the steatosis as being of a moderate degree if involving from 30 to 60%, and as a severe degree if involving over 60%. In our work, one of the criteria of the refusal from surgery was the fatty degeneration exceeding 50% of the graft parenchyma.

The results of this study have confirmed a very high informative value and a clinical significance of a rapid liver biopsy processing in predicting the liver graft function. The implementation of the rapid histologic evaluation technique has reduced the incidence of severe IRI by over twice. A careful selection of donor organs, based, inter alia, on the results of rapid biopsy processing has led to a reduction in the incidence of severe graft dysfunction from 7 to 0.6%. Using the rapid histologic evaluation in clinical transplantation does not prolong the graft cold ischemia time, which should certainly be attributed to the benefits of this technique. In this respect, our data are completely consistent with the data from literature [19]. Besides, our results have shown that the rapid histologic evaluation technique allowed a justified and safe expansion of the donor pool by including aged donors that is especially important in critical shortage of donor organs.

Conclusion

A rapid histologic evaluation as a routine study in a complex assessment of a liver graft reduces the incidence of severe graft dysfunction, including PGNF, thereby positively affecting the overall outcome of surgery.

Further research is needed for the implementation of non-invasive techniques to assess a graft functional viability.

References

1. Pogrebnichenko I.V. Effective use of multi organ donor liver transplantation: Dr. med. sci. diss. Moscow, 2014. 143 p. (In Russian).

2. Angelico M. Donor liver steatosis and graft selection for liver transplantation: a short review. *Eur Rev Med Pharmacol Sci.* 2005;9(5):295–297.

3. Feng S., Goodrich N.P., Bragg-Gresham J.L., et al. Characteristics Associated with Liver Graft Failure: The Concept of a Donor Risk Index. *Am J Transplantat.* 2006;6(4):783–790.

4. Siniscalchi A., Gamberini L., Laici C., et al. Post reperfusion syndrome during liver transplantation: From pathophysiology to therapy and preventive strategies. *World J Gastroenterol.* 2016;22(4):1551–1569.

5. Busuttil R.W., Klintman G.B. *Transplantation of the Liver.* 3rd ed. Elsevier, 2015. 1569 p.

6. Boyer T., Wright T., Manns M. *Zakim and Boyer's hepatology. A text book of liver disease: 2-Volume Set.* 5th ed. Philadelphia, PA : Saunders Elsevier, 2006. 1578 p.

7. Khubutiya M.Sh., Gulyaev V.A., Zimina L.N., et al. Comprehensive assessment of the liver after the laparotomy in multiorgan donors. *Vestnik transplantologii i iskusstvennykh organov.* 2012;1:41–49. (In Russian).

8. Hao Chen, Junjie Xie, Baiyong Shen, et al. Initial poor graft dysfunction and primary graft non-function after orthotopic liver

transplantation. In: Mizuguchi Y., ed. *Liver Biopsy in Modern Medicine*. InTech, 2011. 183–206.

9. Ploeg R.L., D'Alessandro A.M., Knechtle S.J., et al. Risk factor for primary dysfunction after liver transplantation – a multivariate analysis. *Transplantation*. 1993;55(4):807–813.

10. Gonzalez F.X., Rimola A., Grande L., et al. Predictive factors of early postoperative graft function in human liver transplantation. *Hepatology*. 1994;20(3):565–573.

11. Otthoff K.M., Kulik L., Samstein B., et al. Validation of a current definition of early allograft dysfunction in liver transplant recipients and analysis of risk factors. *Liver Transplantation*. 2010;16(8):943–949.

12. Nanashima A., Pillay P., Verran D., et al. Analysis of initial poor graft function after orthotopic liver transplantation: experience of an australian single liver transplantation center. *Transplant Proc*. 2002;34(4):1231–1235.

13. Silberhumer G.R., Pokorny H., Hetz H., et al. Combination of extended donor criteria and changes in the Model for End-Stage Liver Disease score predict patient survival and primary dysfunction in liver transplantation: a retrospective analysis. *Transplantation*. 2007;83(5):588–592.

14. Maring J.K., Klompaker I.J., Zwaveling J.H., et al. Poor initial graft function after orthotopic liver transplantation: can it be predicted and does it affect outcome? An analysis of 125 adult primary transplantations. *Clin Transplant*. 1997;11(5) Pt 1:373–379.

15. D'Alessandro A.M. Liver transplantation: Expanding donor pool. American society of transplant surgery. Available at:

<http://asts.org/docs/default-source/resource/liver-transplantation-nbsp-expanding-the-donor-pool.pdf?sfvrsn=0>

16. Zamboni F., Franchello A., David E., et al. Effect of macrovescicular steatosis and other donor and recipient characteristics on the outcome of liver transplantation. *Clin Transplant*. 2001;15(1):53–57.

17. Crowley H., Levis W.D., Gordon F., et al. Steatosis in donor and transplant liver biopsies. *Hum Pathol*. 2000;31(10):1209–1213.

18. Chu M.J.J., Hickey A.J., Phillips A.R., Bartlett A.S The Impact of Hepatic Steatosis on Hepatic Ischemia-Reperfusion Injury in Experimental Studies: A Systematic Review. *BioMed Res Int*. 2013;2013:192029.

19. Ravaioli M., Grasi G.L., Cescon M., et al. Liver transplantations with donor aged 60 years and above: the low liver damage strategy. *Transplant International*. 2009;22(4):423–433.

20. Adani G.L., Baccarani U., Sainz-Barriga M., et al. The role of hepatic biopsy to detect macrovacuolar steatosis during liver procurement. *Transplant Proc*. 2006;38(5):1404–1406.

21. Imber C.J., St Peter S.D., Lopez I., et al. Current practice regarding the use of fatty livers: a trans-Atlantic survey. *Liver Transpl*. 2002;8(6):545–549.

22. Imber C.J., St Peter S.D., Hand A., Friend P.J. Hepatic steatosis and its relationship to transplantation. *Liver Transplant*. 2002;8(5):415–423.

23. Nocito A., El-Badry A.M., Clavien P.A. When is steatosis too much for transplantation? *J Hepatol*. 2006;45(4):494–499.

24. Dutkowski P., Schlegel A., Slankamenac K., et al. The use of fatty liver grafts in modern allocation systems: risk assessment by the balance of risk (BAR) score. *Ann Surg*. 2012;256(5):861–868.